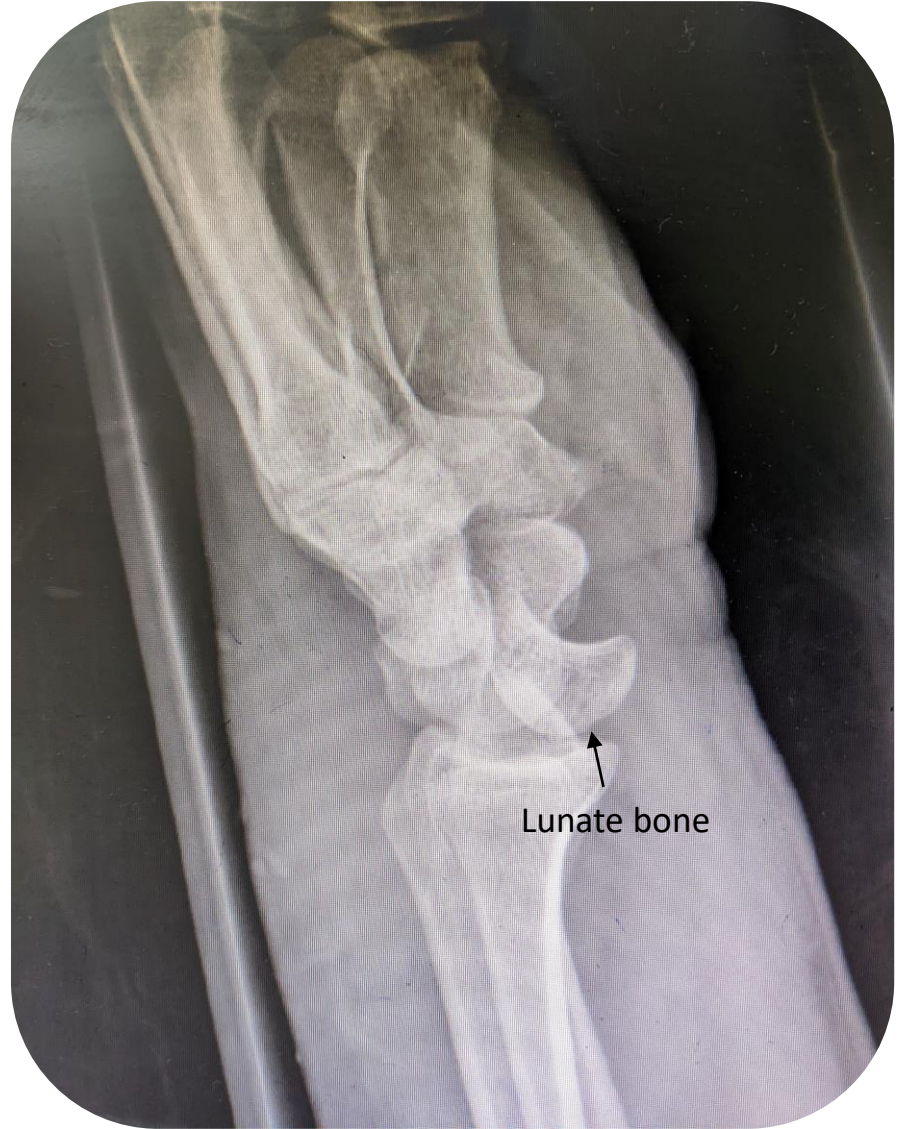

Peri-lunate dislocation

Maedeh Asna Ashari, MD

Assistant Professor of Emergency Medicine

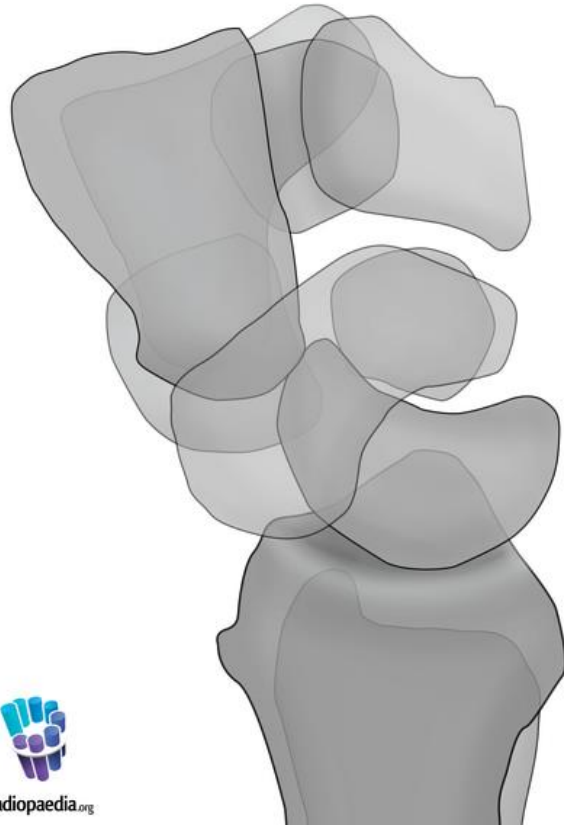


Lunate bone

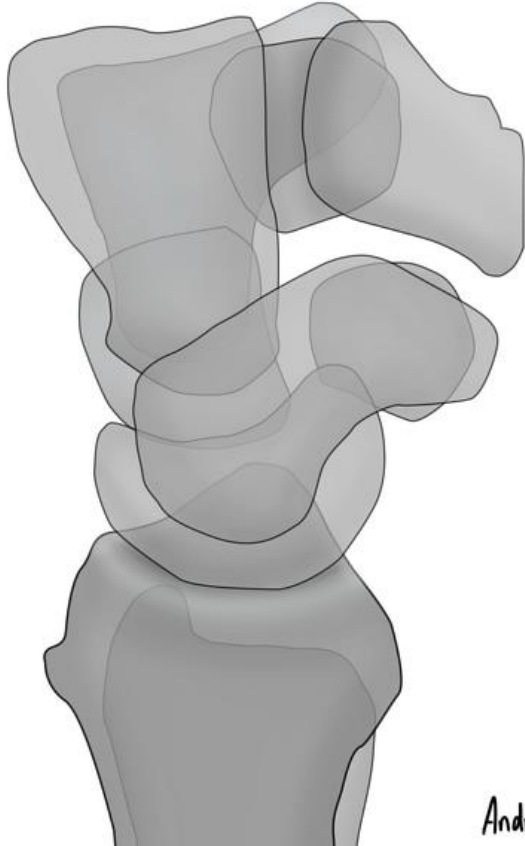
Perilunate dislocation

- In a **perilunate dislocation**, the **capitate** is not vertically aligned with the lunate and radius on a lateral view of the wrist.
- The lunate and radius remain correctly aligned.

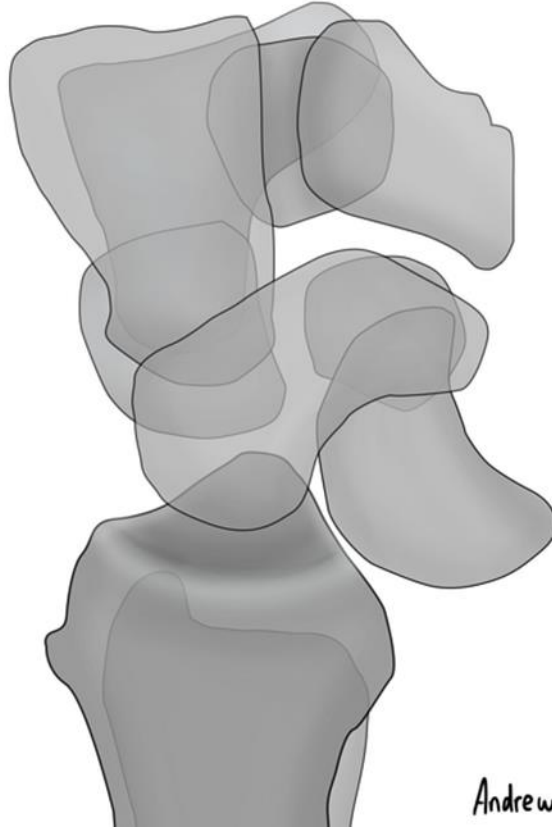
Perilunate dislocation



Normal



Lunate dislocation



Perilunate dislocation

